



ELSEVIER



Implant-based immediate breast reconstruction in the previously augmented patient



Jason Roostaeian*, Alfred P. Yoon, Paymon Rahgozar, Neil Tanna, Christopher A. Crisera, Andrew L. Da Lio, Jaco H. Festekjian

University of California Los Angeles, Division of Plastic & Reconstructive Surgery, Los Angeles, CA 90095, USA

Received 28 June 2014; accepted 11 January 2015

KEYWORDS

Breast reconstruction;
Breast implants;
Prior augmented;
Previously augmented;
Capsular contracture

Summary *Background:* Millions of women have undergone augmentation mammoplasty with implants and breast cancer continuing to be the most common non-cutaneous malignancy in female patients. Reconstructive surgeons will inevitably encounter breast cancer patients with prior augmentation. Implant-based techniques represent the most common form of breast reconstruction overall and remains a common option among those who were previously augmented.

Objective: The purpose of this study is to evaluate outcomes of implant-based reconstruction in previously augmented women.

Methods: A retrospective review from September 2004 to December 2009 was performed. 38 women (63 breasts) with a history of prior augmentation (PA) who underwent implant-based reconstruction were identified and compared to a non-prior augmented (NPA) control group (77 patients; 138 breasts). Normative data, augmentation details, reconstruction method, complication rates, and revision rates were evaluated.

Results: The total complication rate was significantly different between the two groups with 18 complications (28.6%) occurring in 9 PA breasts and 20 complications (14.5%) in 19 NPA breasts (p-value 0.037). When analyzed by specific complication subtypes, capsular contracture was the only complication that bordered significance between the two cohorts (p-value 0.057). Complication rates were otherwise similar regardless of augmentation or reconstruction type.

* Corresponding author. Division of Plastic & Reconstructive Surgery, University of California Los Angeles, 200 Medical Plaza, Suite 465, Los Angeles, CA 90095, USA. Tel.: +1 (310) 206 7521; fax: +1 (310) 206 3028.

E-mail address: jasonroostaeian@mednet.ucla.edu (J. Roostaeian).

Conclusion: Implant-based reconstruction is a safe option for previously augmented patients that is able to provide outcomes similar to non-augmented patients. Results are not affected by the location of previous implants or the implant-based reconstruction method. There may be a higher incidence of capsular contracture in the previously augmented patient that warrants further investigation and preoperative discussion.

© 2015 British Association of Plastic, Reconstructive and Aesthetic Surgeons. Published by Elsevier Ltd. All rights reserved.

Introduction

The development of augmentation mammoplasty dates back to 1962 with the work of Cronin, Gerow, and Dow Corning. Since then the number of augmentation mammoplasty procedures performed each year has shown persistent growth, and remains to be one of the most common procedures performed by plastic surgeons today.¹ According to the American Society of Plastic Surgeons, more than 280,000 Americans underwent cosmetic breast augmentation in 2012.¹ In total, it has previously been estimated that more than 2 million women have undergone augmentation mammoplasty in the United States.² With more than three-hundred thousand augmentations performed each year, this number continues to grow.

Breast cancer represents the most common non-cutaneous malignancy in the female population and will affect one in every eight women.³ Therefore as time progresses and the population of women with augmentation matures, it is no surprise that the reconstructive surgeon will encounter more and more patients with breast cancer that have had prior augmentation.

While many options are available for breast reconstruction, previous series have shown that patients with a history of prior augmentation were more likely to have implant based reconstruction.^{4–8} Moreover, patients with a history of prior augmentation tend to have a lower BMI and therefore are often not good candidates for typical autologous techniques.^{2,9}

Although many of the health and safety issues, including the frequency/stage of breast cancer and the effect on screening, associated with breast augmentation have been thoroughly discussed over the past couple decades, the literature is relatively sparse with regards to characteristics and outcomes of post-mastectomy reconstruction in previously augmented patients.^{4–8} A few recent studies have explored the reconstruction outcomes of prior augmented patients.^{10–12} The purpose of our study was to compare the outcomes of implant-based reconstruction in women who have had prior breast augmentation to a control group of patients who have not. To our knowledge, this study is the largest study comparing reconstruction outcomes and complications of previously augmented patients to non-augmented patients.

Patients and methods

A retrospective chart review of all patients who underwent implant-based breast reconstruction following skin-sparing

mastectomy between September 2004 and December 2009 was performed. All women with a history of prior augmentation (PA) within the group were identified. During that time frame, a total of 345 patients (571 breasts) underwent implant-based breast reconstruction. From that group, 38 patients (63 breasts) had a prior history of breast augmentation. For comparison we randomly selected one of every four women (25%) without a history of previous augmentation over the time period, which totaled 77 patients (138 breasts). All patients had undergone skin-sparing mastectomy. Patients who underwent nipple-sparing mastectomy were excluded. Implants/expanders were placed in a subpectoral pocket with an acellular dermal sling in all patients.

Demographic variables including: height, weight, body mass index, preoperative breast cup size, degree of preoperative ptosis, and surgical risk factors such as smoking, previous radiation therapy, or significant co-morbidities were evaluated for all patients. Details pertaining to their prior augmentation including: implant type, volume, and position (subglandular versus subpectoral) were recorded. Details of the implant or tissue expander type, intra-operative fill volume, total operative time, and final permanent implant volume were recorded. Postoperative complications including seroma, hematoma, infection, or capsular contracture were recorded for all patients. Capsular contracture was graded on Baker scale 1 through 4 by the operating surgeons at postoperative follow-up. Capsulectomy or capsulorrhaphy were performed to revise capsular contractures unless the patient refused the operation. We also examined whether revisional surgery was performed and the total number of revisions necessary for each group.

Pearson's chi-square and Fisher's exact test were used for all unadjusted bivariate categorical data comparisons. Student's t-test was used for pairwise continuous data comparisons. Poisson regression was used to estimate the relationship between number of complications and prior augmentation status, prior implant location, and reconstruction procedure type. A p-value < 0.05 was considered statistically significant. All statistics were performed using statistical package R.

Results

A total of 11 patients (19 breasts) from the 38 previously augmented group underwent immediate placement of a permanent silicone implant at the time of mastectomy (Figure 1). Six of these patients had undergone prior

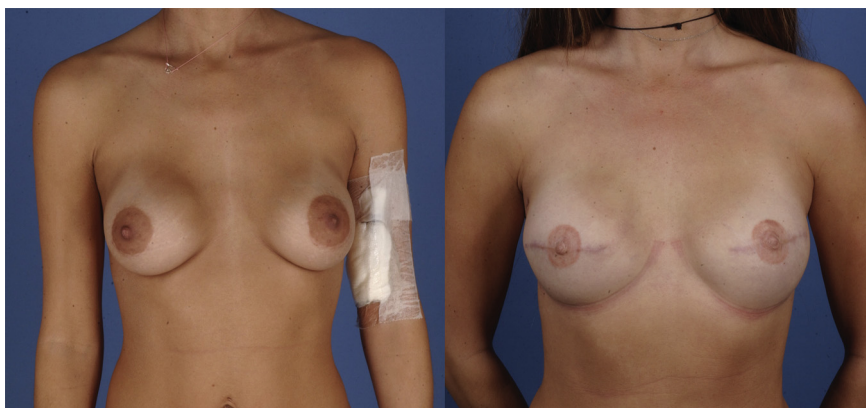


Figure 1 Preoperative (left) and postoperative (right) views of a 34-year-old prior-augmented patient who underwent bilateral mastectomy and immediate implant breast reconstruction (IIBR) after discovery of stage 1 right breast cancer. She sustained no postoperative complications. Preoperative photo was taken in February 2006. Postoperative photo were taken in March 2007.

subglandular augmentation and five were subpectoral. A total of 27 patients with previous history of augmentation underwent immediate placement of a tissue expander at the time of mastectomy (Figure 2). 11 of these patients had undergone prior subglandular augmentation and 16 had undergone prior subpectoral augmentation. Therefore a total of 17 patients underwent prior subglandular augmentation and 21 patients underwent prior subpectoral augmentation. In comparison, 28 patients and 49 patients of the control group underwent immediate placement of a permanent silicone implant or tissue expander, respectively (Figure 3).

Both cohorts were found to be similar in most preoperative demographic variables except for preoperative cup size, which was expected (Table 1). The prior augmented (PA) group trended towards a greater number of breasts that were D-cup or larger and less breasts that were A-cup when compared to those of the non-prior augmented (NPA) group (p-value 0.06; 0.02). The only trending differences in indication for mastectomy between the groups were mastectomy for prophylaxis and DCIS (Table 2). Postoperative variables including type of procedure performed—immediate implant breast reconstruction (IIBR), indicating direct to implant

reconstruction, or tissue expander breast reconstruction (TEBR), length of time during the operation, and follow-up since the initial reconstruction were similar in both cohorts (Table 3). There was no significant difference between the number of breasts receiving pre and postoperative XRT between the two groups as well (p-value 0.76; 0.33). However, a significant difference was seen in the final reconstructed breast volume; the average reconstructed breast volume was greater in the PA group (455.27cc) compared to the NPA group (395.82cc) (Table 3; p-value 0.0005).

When comparing by patients, postoperative total complication rates were higher in PA patients than NPA patients, but not statistically different between the two groups; 14 complications (36.8%) by patient in the PA group vs. 16 complications (20.8%) by patient in the NPA group (p-value 0.11). However, postoperative total complication rates were significantly different between the two groups when comparing breasts; 18 complications (28.6%) by breast in the PA group vs. 20 complications (14.5%) by breast in the NPA group (p-value 0.037; Table 4). Regression analysis of the number of complications and prior augmentation status also demonstrated statistical significance (Figure 4). The only nearly statistically significant

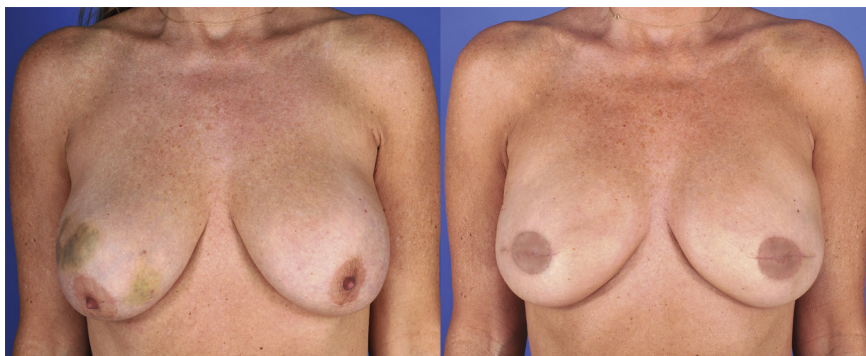

Figure 2 Preoperative (left) and postoperative (right) views of a 50-year-old prior-augmented patient who underwent bilateral mastectomy and tissue expander breast reconstruction (TEBR) after discovery of a grade 1 right breast tumor. She sustained no postoperative complications. Preoperative photo was taken in November 2010. Postoperative photo was taken in May 2011.

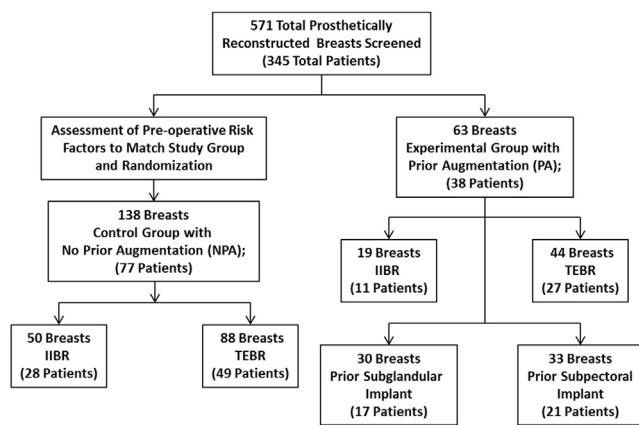


Figure 3 Study Design. Between 2004 and 2009, 571 total prosthetically reconstructed breasts were screened from 345 patients. The experimental group consisted of 63 prior augmented (PA) breasts in 38 patients. Preoperative risk factors of the PA group were assessed to find a similar cohort of non-prior augmented (NPA) patients to form the control group. 138 breasts from 77 patients were randomly selected to comprise the NPA group. The control and experimental groups were divided into respective subgroups based on prior implant pocket type and reconstruction procedure type to further assess outcomes and complications.

complication rate between the two groups was the capsular contracture rate. 14.3% of PA breasts and 5.8% of NPA breasts had capsular contracture (p-value 0.057) (Table 4). Of the 9 PA breasts that had capsular contracture, 8 (88.9%) underwent mastectomy due to cancer and only one (11.1%) underwent prophylactic mastectomy. No correlation between radiotherapy and capsular contracture was

Table 1 Baseline characteristics of patients.

Demographics	PA group	Non-PA group	p-value
Patients	38	77	—
Breast	63	138	—
Unilateral	13 (34.2%)	16 (20.8%)	0.17 ^a
Bilateral	25 (65.8%)	61 (79.2%)	0.17 ^a
Mean age	47.0	46.1	0.62 ^b
Mean BMI (kg/m ²)	22.5	21.7	0.17 ^b
Co-morbidities	8 (21.1%)	15 (19.5%)	1.00 ^a
Smoking	4 (10.5%)	8 (10.4%)	1.00 ^a
XRT pre op (by breast)	3 (4.8%)	9 (6.5%)	0.76 ^a
Chemo (by breast)	9 (14.2%)	30 (21.7%)	0.25 ^a
Ptosis > grade 1 (by breast)	15 (23.8%)	28 (20.3%)	0.58 ^a
Pre-op ≥ D-cup breast (by breast)	18 (28.6%)	23 (16.7%)	0.06 ^{a,c}
Pre-op B or C cup breast	38 (60.3%)	80 (58.0%)	0.88 ^a
Pre-op A cup breast	7 (11.1%)	35 (25.3%)	0.02 ^d

^a Fisher exact test.
^b Student's T-test.
^c Statistical trend.
^d Significance.

Table 2 Indications by breast.

Indications	PA group	Non-PA group	p-value
Prophylactic	24 (38.1%)	73 (52.9%)	0.07 ^{a,b}
DCIS	23 (36.5%)	32 (23.2%)	0.06 ^{a,b}
Invasive CA	16 (25.4%)	29 (21.0%)	0.58 ^a
LCIS	0 (0.0%)	4 (2.9%)	0.31 ^a

^a Fisher exact test.
^b Statistical trend.

demonstrated in the 8 breasts that had capsular contracture after cancer-induced mastectomy (2 had exposure to radiotherapy and 6 did not).

All the accounted patients with capsular contracture had Baker's 3 or 4 and capsulectomy was either performed or recommended. Even though not statistically significant, no skin flap necrosis (0.0%) occurred in the PA group while 3 (2.2%) incidences were present in the NPA group.

None of the reconstructed breasts in the PA group had implant rupture while 1 of the 138 reconstructed breasts (0.7%) in the NPA group suffered implant deflation necessitating implant exchange (Table 4). This occurred in a patient who underwent bilateral reconstruction with 475cc saline implants and developed an acute deflation of the right implant approximately 2.5 years post-reconstruction. Implant loss occurred in one reconstructed breast (1.6%) in the PA group that was reconstructed with an IIBR procedure. The patient had recurrent breast wound dehiscence and the implant was eventually removed because she required extensive radiotherapy. Implant loss occurred in one patient as well in the NPA group that was also previously reconstructed using an IIBR procedure. This patient had bilateral mastectomies and reconstruction with 600cc saline implants. Subsequently, she developed extensive skin necrosis of the left breast which precluded closure of the wound without removal of implant. Therefore, successful implant reconstruction was ultimately achieved in 97% of patients and 98% of breasts in the PA group and 99% of patients and breasts in the NPA group (p-value 1).

Infectious complications were present in two breasts in the PA group and one breast in the NPA group (p-value

Table 3 Intra and post-operative characteristics by breast.

Characteristics	PA group	Non-PA group	p-value
IIBR	19 (30.2%)	50 (36.2%)	0.43
TEBR	44 (69.8%)	88 (63.8%)	0.43
XRT post op	5 (7.7%)	6 (4.3%)	0.33 ^a
Post recon breast volume	455.27cc	395.82cc	0.0005 ^{b,c}
Silicone final implant	57 (90.5%)	113 (81.9%)	0.14 ^a
Saline final implant	6 (9.5%)	25 (18.1%)	0.14 ^a
Mean OR time	3.6 h	3.8 h	0.53 ^b
Mean follow up months	15.3	12.8 months	0.29 ^b

^a Fisher exact test.
^b Student's T-test.
^c Significance.

Table 4 Comparison of complication rates by breast.

Complication	PA group	Non-PA group	p-value
Total complications occurrences	18	20	0.037 ^{b,c}
Infection	2 (3.2%)	1 (0.7%)	0.23 ^a
Hematoma	2 (3.2%)	1 (0.7%)	0.23 ^a
Seroma	0 (0.0%)	1 (0.7%)	1.00 ^a
Dehiscence	3 (4.8%)	1 (0.7%)	0.09 ^a
Wound complication	0 (0.0%)	1 (0.7%)	1.00 ^a
Skin Flap necrosis	0 (0.0%)	3 (2.2%)	0.55 ^{a,d}
Capsular contracture	9 (14.3%)	8 (5.8%)	0.057 ^{a,d}
Hypertrophic scarring	0 (0.0%)	2 (1.4%)	1.00 ^a
Implant exchange	1 (1.6%)	0 (0.0%)	0.31 ^a
Implant loss	1 (1.6%)	1 (1.4%)	1.00 ^a
Implant rupture	0 (0.0%)	1 (0.7%)	1.00 ^a

^a Fisher exact test.

^b Chi-squared test after poisson regression model.

^c Significance.

^d Statistical trend.

0.23). The infectious complications in two out of three patients were very mild superficial skin infection treated conservatively with oral antibiotics. But one patient in the PA group had a severe infection that necessitated an operative incision and drainage and IV antibiotics. This occurred after the patient developed severe capsular contracture following postoperative XRT. She also had a hematoma following her initial reconstruction that was likely due to her anti-coagulant regimen for her prior cardiac valve-replacement surgery. The tissue expander was later replaced and ultimately successful reconstruction was achieved without further complications.

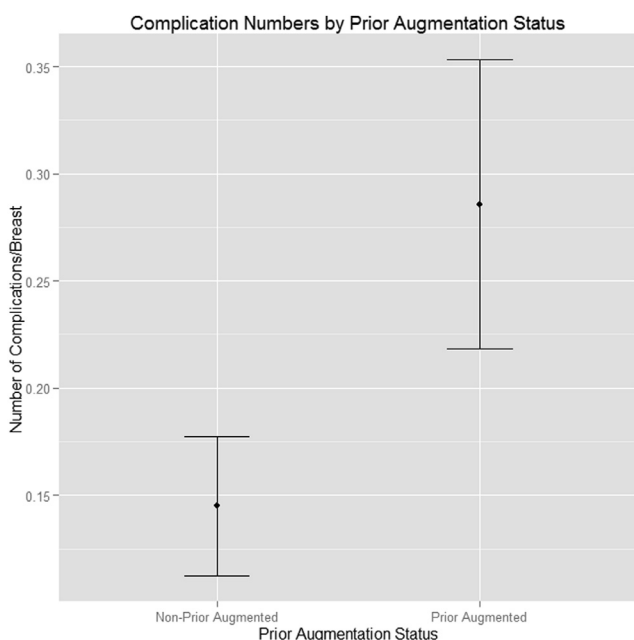


Figure 4 Poisson regression comparing the number of complications by breast depending on prior augmentation status. Distinct standard error bars indicate significant difference in number of complications between the two cohorts.

During our follow-up period, the number and type of revision surgeries done due to complications were not significantly different between the two groups (Table 5). Of note, we did not count minor revisions that were performed during implant exchange as this does not add an additional unplanned operation.

Further subgroup analysis of PA patients with prior subglandular versus subpectoral implants were conducted. When compared by breasts, many of the pre and post-operative characteristics of these two cohorts were similar (Table 6). However, two categories that significantly differed between the groups were size of prior implant and post-reconstructive breast volume. The average size of pre-existing implants in the prior subpectoral group was higher compared to the average size in the prior subglandular group (364.74cc vs. 298.79 cc; p-value 0.01). Similarly, the average post-reconstructive breast volume in the prior subpectoral group was larger than that of the prior subglandular group (493.27 cc vs. 413.47 cc; p-value 0.004) (Table 6). The mean length of operative time were not significantly different between the prior subglandular and subpectoral subgroups; however, the prior-subpectoral cohort tended to have a slightly shorter operative time than its counterpart group (3.60 h vs. 3.84 h; p-value 0.08). No significant differences in complication rates, including capsular contracture rates, were observed between patients who were previously augmented with sub-glandular versus sub-pectoral implants (Table 7). Regression analysis of the number of complications and prior implant locations also demonstrated similar outcomes between the two cohorts (Figure 5).

The proportion of immediate implant breast reconstruction (IIBR) to tissue expander breast reconstruction (TEBR) surgeries between the PA and NPA groups were similar (Table 3; p = 0.43). Subsequently, another subgroup analysis exploring the characteristics and complications of PA breasts reconstructed using IIBR and TEBR was conducted. The PA-IIBR cohort had a significantly larger size of prior implant compared to that of the TEBR cohort (p-value 0.013); however, the PA-TEBR cohort had a significantly larger post-reconstruction breast volume than the IIBR cohort (Table 8; p-value 0.016). The total complication rates as well as individual complication rates were similar between the two groups (Table 9). Regression analysis of the number of complications and reconstruction

Table 5 Comparison of revisions due to complication by breast.

Reasons for revision	PA group	Non-PA group	p-value
Total revision surgeries	8	17	1.00 ^a
Infection	1 (1.6%)	0 (0.0%)	0.31 ^a
Hematoma evac	1 (1.6%)	1 (0.7%)	0.53 ^a
Seroma aspiration	0 (0.0%)	1 (0.7%)	1.00 ^a
Scar revision	0 (0.0%)	2 (1.4%)	1.00 ^a
Skin flap necrosis	0 (0.0%)	4 (2.8%)	0.31 ^a
Diheiscence	3 (4.8%)	1 (0.7%)	0.09 ^a
Capsular contracture	3 (4.8%)	7 (5.0%)	1.00 ^a
Ruptured implant	0 (0.0%)	1 (0.7%)	1.00 ^a

^a Fisher exact test.

Table 6 Characteristics of PA group by prior implant location.

Characteristics	Prior subglandular implant	Prior-subpectoral implant	p-value
Total number of breasts	30	33	0.21 ^a
XRT post op	3 (10.0%)	2 (6.1%)	0.66 ^a
Size of prior implant	298.79 cc	364.74 cc	0.01 ^{b,c}
Post recon breast volume	413.47 cc	493.27 cc	0.004 ^{b,c}
Prior saline implant	13 (43.3%)	20 (60.6%)	0.21 ^a
Prior silicone implant	17 (56.7%)	13 (39.4%)	0.21 ^a
Mean OR time	3.84 h	3.60 h	0.08 ^b
Mean follow up	20.69 months	16.29 months	0.24 ^b

^a Fisher exact test.

^b Student's T-test.

^c Significance.

procedure types also demonstrated similar outcomes between the two cohorts (Figure 6).

Discussion

Literature that discusses operative management and outcomes of previously augmented breast reconstruction patients is limited. A few recent studies compared reconstructive outcomes in prior augmented and non-augmented patients, but to our knowledge this is the largest series comparing reconstruction complications of prior augmented and non-augmented patients.^{10–12} In 2001, Spear et al. reported a series of previously augmented women that was treated primarily with implant based reconstruction.⁵ This study, however, was performed before the widespread use of acellular dermal matrix and details of operative approach and outcomes were limited. It was noted, however, that patients with previous subpectoral augmentation were ideal candidates for secondary reconstruction to a partially or fully formed prosthetic pocket. Indeed, reconstruction with implants was less common in patients with previous subglandular augmentation in that series. One issue may have been pectoral retraction without a well formed subpectoral pocket given the extensive suprapectoral dissection for the mastectomy.

The advent of acellular dermal matrix has allowed for greater control of the implant pocket, and minimized postoperative pectoral retraction ("windowshading"), and thereby may improve the results of implant based reconstruction in the patient that has had previous subglandular in addition to submuscular augmentation.

Treatment options for prior augmentation patients with invasive breast cancer include breast conservation therapy with or without implant removal and mastectomy with breast reconstruction. Breast conservation therapy requires sufficient tumor resection, vigilant observation of the augmented breast, and radiation therapy that may compromise patient satisfaction and outcome. In addition, difficulty of achieving a tumor-free margin and decreased amount of native breast tissue may become obstacles to the surgeon. Because of these challenges, more prior augmented patients elect to undergo mastectomy and breast reconstruction rather than breast conservation therapy.^{2,7} Our study focuses on prior augmentation patients undergoing total mastectomy and implant-based reconstruction to reflect this growing patient group.

While autologous techniques are great option for breast reconstruction in many patients, it may not be ideal for the previously augmented patient. For example, with low body mass index, there may be insufficient abdominal and gluteal donor tissue for autologous-based options.^{2,9} In

Table 7 Comparison of complication rates in PA group by prior implant location.

Complications	Prior subglandular implant	Prior-subpectoral implant	p-value
Total complication occurrences	7	11	0.46 ^b
Infection	1 (3.3%)	1 (3.0%)	1.00 ^a
Hematoma	0 (0.0%)	2 (6.0%)	0.49 ^a
Seroma	0 (0.0%)	0 (0.0%)	1.00 ^a
Dehiscence	1 (3.3%)	2 (6.1%)	1.00 ^a
Wound complication	0 (0.0%)	0 (0.0%)	1.00 ^a
Skin flap necrosis	0 (0.0%)	0 (0.0%)	1.00 ^a
Capsular contracture	5 (16.7%)	4 (12.1%)	0.73 ^a
Hypertrophic scarring	0 (0.0%)	0 (0.0%)	1.00 ^a
Implant loss	0 (0.0%)	2 (6.1%)	0.49 ^a
Implant rupture	0 (0.0%)	0 (0.0%)	1.00 ^a

^a Fisher exact test.

^b Chi-squared test after poisson regression model.

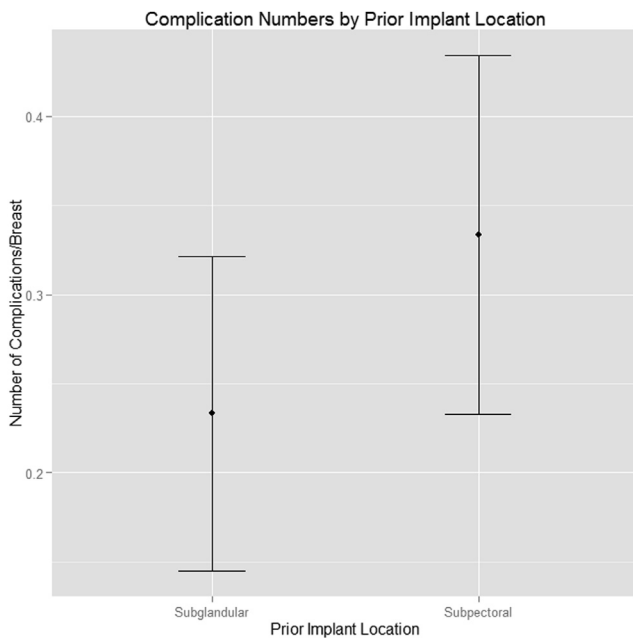


Figure 5 Poisson regression comparing number of complications in prior-augmented breasts with subglandular or subpectoral implants. The overlap of the standard error bars indicate that the number of complications do not differ depending on prior implant locations in the prior augmented group.

addition, some women may not be willing to accept the donor site morbidity, longer operative time, and prolonged hospitalization inherent in autologous reconstruction. This was thought to be attributable to the willingness of the augmentation population to have implants, their relatively smaller breast size/modest weight, and lack of sufficient donor tissue for autologous options.⁵

Patients with prior augmentations differ in many ways from the cohort without augmentation. Anatomical

Table 9 Comparison of complication rates in PA group by procedure type.

Complications	Immediate implant	Tissue expander	p-value
Total complication occurrences	8	10	0.19 ^b
Infection	0 (0.0%)	2 (4.5%)	1.00 ^a
Hematoma	1 (5.3%)	1 (0.0%)	0.09 ^a
Seroma	0 (0.0%)	0 (0.0%)	1.00 ^a
Dehiscence	2 (10.5%)	1 (2.3%)	1.00 ^a
Wound complication	0 (0.0%)	0 (0.0%)	1.00 ^a
Skin Flap necrosis	0 (0.0%)	0 (0.0%)	1.00 ^a
Capsular contracture	4 (21.1%)	5 (11.4%)	0.43 ^a
Hypertrophic scarring	0 (0.0%)	0 (0.0%)	1.00 ^a
Implant loss	1 (5.3%)	1 (2.3%)	0.52 ^a
Implant rupture	0 (0.0%)	0 (0.0%)	1.00 ^a

^a Fisher exact test.

^b Chi-squared test after Poisson regression model.

differences in prior augmentation patients include small native breast volume and implant induced attenuation of the adjoining tissue that can create pre and postoperative challenges.⁷ As our data shows, PA patients tend to have larger breast volume prior to reconstruction due to augmentation. Karanas et al. observed that less than 50 percent of native breast tissue remained in prior augmentation patients at the time of cancer diagnosis.⁷ A small native breast volume lends susceptibility to insufficient resection and lumpectomy that may compromise cosmesis. Studies have shown that self-confidence and self-esteem are correlated with breast appearance in augmentation patients.^{13,14} A greater investment in appearance in the prior augmentation group may affect patient satisfaction rates after breast reconstruction. Spear et al. observed that patient satisfaction rates after breast reconstruction were generally higher in the prior augmented group compared to the non-augmented group.⁵

The prevalence of prophylactic mastectomy and reconstruction was higher in the non-augmented group while the reconstruction rate for DCIS was higher in the prior-augmented group. We are uncertain why such differences were observed. One hypothetical reason may be because prior augmented patients might potentially derive more self-confidence from breast appearance than non-prior augmented patients, deterring these patients from undergoing prophylactic mastectomy. Another potential reason is because the bilateral prophylactic rate in non-augmented patients (79.2%) is higher than that of prior-augmented patients (65.8%); likely because matching a prior-augmented breast in appearance with an implant-reconstructed breast is easier than trying to match a natural breast.

Recent studies based on smaller patient numbers concluded that there was no significant difference in overall or individual complications between prior augmented and non-augmented group.^{10,11} Another study reported similar findings except irradiated prior-augmented breasts tended

Table 8 Characteristics of PA group by procedure type.

Characteristics	Immediate implant	Tissue expander	p-value
Total number of breasts	19	44	<0.001 ^{a,c}
XRT post op	2 (10.5%)	3 (6.8%)	0.63 ^a
Size of prior implant	389.00 cc	319.46 cc	0.013 ^{b,c}
Post recon breast volume	404.00 cc	477.41 cc	0.016 ^{b,c}
Prior saline implant	9 (47.4%)	24 (54.5%)	0.78 ^a
Prior silicone implant	10 (52.6%)	20 (45.5%)	0.78 ^a
Mean OR time	3.76 h	3.73 h	0.94 ^b
Mean follow up	16.72 months	17.53 months	0.84 ^b

^a Fisher exact test.

^b Student's T-test.

^c Significance.

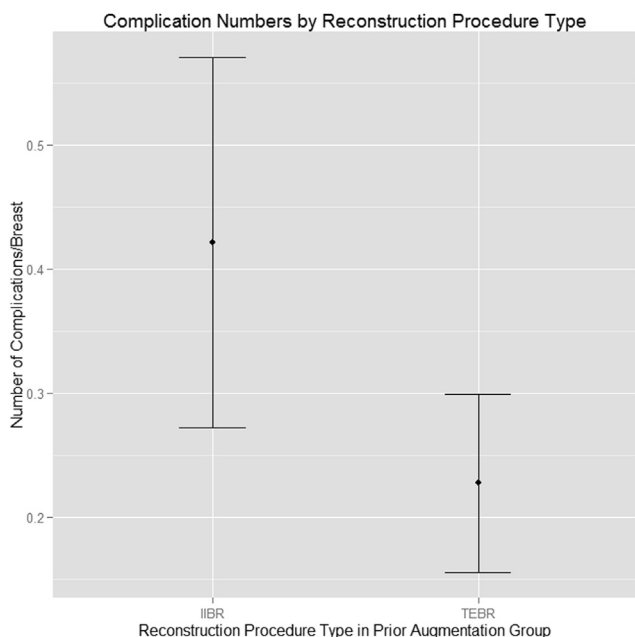


Figure 6 Poisson regression comparing number of complications in prior augmented breasts that were reconstructed using immediate implant breast reconstruction (IIBR) vs. tissue expander breast reconstruction (TEBR). The overlap of the standard error bars indicate that the number of complications do not differ depending on reconstruction procedure type.

to have higher rate of implant loss than non-augmented breasts.¹² Our study found total complication rates between the two groups to be significantly different—the main complication type contributing to this finding was the difference in capsular contracture rates between the prior augmented group and the control group. Past studies have suggested that capsular contracture is caused by a subclinical bacterial infection on the biofilm surface of the implant.^{15–17} We speculate that residual biofilms or capsules from the previous augmentation implant may increase the chances of capsular contracture after breast reconstruction with a new implant. It has been shown that preoperative antibiotics in the setting of augmentation mammoplasty did not decrease the rate of capsular contracture, most likely due to the deep-seated bacteria within the biofilms.¹⁸ But given the power of our series and the borderline significance, further study of this finding is necessary.

Although not statistically significant, another notable difference in complication rate between the prior and non-prior augmented groups is skin flap necrosis. The lack of any skin flap necrosis in the prior augmented patients may potentially be attributed to a delay type phenomenon of the breast skin flaps given the history of prior augmentation. Having had prior disruption of some of the underlying perforators from the pectoralis and breast gland may improve the vascularity of the skin flaps and make them more resistant to necrosis. All procedures were performed by the same group of surgical oncologists and plastic surgeons at UCLA, whom were evenly distributed across both NPA and PA groups; therefore, surgeon related bias is an unlikely explanation for this finding. Even though our study did not demonstrate statistical

significance to corroborate this theory, further higher power studies are warranted to investigate this potential difference.

The only significant differences we found between the prior subglandular implant and the prior subpectoral implant subgroups were the size of prior implant and post-reconstructive breast volume. The fact that larger augmentation volumes would lead to larger post-reconstructed volumes is an expected finding and can be attributed to greater expansion of the breast skin envelope which can in turn accommodate larger volumes. Therefore, we can conclude that mastectomy and reconstruction outcomes of prior augmented patients are not dependent upon the pocket type of the previous implant. This statement is further supported by the similar rates of postoperative complications including capsular contracture rates in the subglandular and subpectoral implant subgroups in our series. This finding, however, may be secondary to the advent of human acellular dermal matrix which has allowed for greater pocket control, as we have noted above. Spear et al. noted an easier reconstruction process for prior subpectoral patients compared to the prior subglandular implant patients.⁵ Our data series did not show a significant difference in length of operative time, a rough measure of surgical difficulty, between the two cohorts but the subpectoral group did have a slightly shorter mean operative time.

The larger prior implant size seen in the PA-IIBR subgroup compared to the PA-TEBR subgroup is most likely why another IIBR procedure was performed since the breast envelope was already large enough for a satisfactory implant. On the contrary, the smaller prior implant size in the TEBR subgroup probably necessitated a tissue expander to stretch the breast envelope over time to place an adequately sized implant the patient desired. This observation is further supported by the larger post-reconstructive breast volume size of the TEBR patients compared to the IIBR patients.

A limitation of this study is that it is retrospective with a small sample size resulting in decreased statistical power, particularly with regards to analysis of complication subtypes. Nevertheless, to our knowledge, this is one of the largest series comparing outcomes in implant-based breast reconstruction between previously augmented and non-previously augmented patients.

Conclusion

In conclusion, our data suggests that prior augmentation patients, regardless of reconstruction type or prior implant location, can achieve overall higher reconstructed implant volumes and satisfactory outcomes in implant-based reconstruction. There may be a slightly increased risk for postoperative capsular contracture with implant-based reconstruction in previously augmented women that warrants further study and the potential need for preoperative discussion in this patient population.

Funding

None.

Conflicts of interest

None declared.

Ethical approval

Not required.

Financial disclosure and products page

All authors have no financial interests including products, devices, or drugs associated with this manuscript. There are no commercial associations that might pose or create a conflict of interest with information presented in this submitted manuscript such as consultancies, stock ownership, or patent licensing arrangements.

References

- American Society of Plastic Surgeons. 2012 top 5 cosmetic surgical procedures. <http://www.plasticsurgery.org/news-and-resources/2012-plastic-surgery-statistics.html> [accessed 27.12.13].
- McCarthy CM, Pusic AL, Disa JJ, Cordeiro PG, Cody III HS, Mehrara B. Breast cancer in the previously augmented breast. *Plast Reconstr Surg* 2007;119(1):49–58.
- American Cancer Society. *Key statistics about breast cancer*. <http://www.cancer.org/cancer/breastcancer/detailedguide/breast-cancer-key-statistics> [accessed 27.12.13].
- Salgarello M, Rochira D, Barone-Adesi L, Farallo E. Immediate breast reconstruction after skin- or nipple-sparing mastectomy for previously augmented patients: a personal technique. *Aesth Plast Surg* 2012/04/01;36(2):313–22.
- Spear SL, Slack C, Howard MA. Postmastectomy reconstruction of the previously augmented breast: diagnosis, staging, methodology, and outcome. *Plastic Reconstr Surg* 2001;107(5):1167–76.
- Robbins CM, Long JN, Fix RJ, de la Torre JI, Vasconez LO. Mastectomy with breast reconstruction in previously augmented patients: indications for implant removal. *Ann Plast Surg* 2008;61(5):500–5.
- Karanas YL, Leong DS, Da Lio A, et al. Surgical treatment of breast cancer in previously augmented patients. *Plastic Reconstr Surg* 2003;111(3):1078–83 [discussion 1084–1076].
- Carlson GW, Moore B, Thornton JF, Elliott M, Bolitho G. Breast cancer after augmentation mammoplasty: treatment by skin-sparing mastectomy and immediate reconstruction. *Plastic Reconstr Surg* 2001;107(3):687–92.
- Grotting JC, Beckenstein MS, Arkoulakis NS. The art and science of autologous breast reconstruction. *Breast J* 2003;9(5):350–60.
- Alperovich M, Choi M, Frey JD, Karp NS. Reconstructive approach for patients with augmentation mammoplasty undergoing nipple-sparing mastectomy. *Aesthet Surg J* 2014;34:1059–65.
- Elliott LF, Chu CK, Daniel J, Harper G, Bergey P. Immediate permanent implant reconstruction following mastectomy with capsule preservation in patients with prior augmentation mammoplasty. *Ann Plast Surg* 2014;72. 0000000000000088.
- Sbitany H, Wang F, Saeed L, et al. Immediate implant-based breast reconstruction following total skin-sparing mastectomy in women with a history of augmentation mammoplasty: assessing the safety profile. *Plast Reconstr Surg* 2014;134:1–9.
- Sarwer DB, LaRossa D, Bartlett SP, Low DW, Bucky LP, Whitaker LA. Body image concerns of breast augmentation patients. *Plastic Reconstr Surg* 2003;112(1):83–90.
- Young VL, Nemecek JR, Nemecek DA. The efficacy of breast augmentation: breast size increase, patient satisfaction, and psychological effects. *Plastic Reconstr Surg* 1994;94(7):958–69.
- Virden C, Dobke M, Stein P, Parsons CL, Frank D. Subclinical infection of the silicone breast implant surface as a possible cause of capsular contracture. *Aesth Plast Surg* 1992/03/01;16(2):173–9.
- Burkhardt BR. Comparing contracture rates: probability theory and the unilateral contracture. *Plastic Reconstr Surg* 1984;74(4):527–9.
- Burkhardt BR, Dempsey PD, Schnur PL, Tofield JJ. Capsular contracture: a prospective study of the effect of local anti-bacterial agents. *Plast Reconstr Surg* 1986;77(6):919–32.
- Gylbert L, Asplund O, Berggren A, Jurell G, Ransjo U, Ostrup L. Preoperative antibiotics and capsular contracture in augmentation mammoplasty. *Plast Reconstr Surg* 1990;86(2):260–7.